

A Strip Free Gingival Graft and a Xenogeneic Collagen Matrix to Increase Keratinized Tissue After Vertical Bone Augmentation

Raquel Jiménez-Tundidor, DDS¹
 Ricardo Marco-Español, MD, DDS¹
 Luis Segura-Mori, DDS, PhD²
 Santiago Bazal-Bonelli, DMD¹
 María Isabel Sánchez-Jorge, DDS, PhD³
 Marko Granić, DDS, PhD⁴
 Jorge Cortés-Bretón Brinkmann, DDS, PhD^{1,5*}
 Juan López-Quiles, MD, DDS, PhD^{1,5}

After vertical bone augmentation (VBA) surgery, loss of both keratinized tissue (KT) and vestibule depth (VD) take place. This article evaluated KT gain, patient satisfaction, and aesthetic outcomes after a modified apically repositioned flap (ARF) in combination with a strip-free gingival graft (FGG) harvested from the palate and a xenogeneic collagen matrix (XCM) to correct mucogingival distortion (MGD) after VBA. This technique minimizes patient morbidity by reducing the need for extensive masticatory mucosa grafts. The study included 12 patients with ≤ 3 mm KT after vertical augmentation procedures. Keratinized tissue gain and tissue thickness were measured. Patient morbidity and aesthetic outcomes were also evaluated. Twenty-four months after surgery, significant VD gain was observed, obtaining a vertical KT augmentation of 5.38 ± 2.06 mm, although tissue thickness increase was only 0.42 ± 0.42 mm. Regarding patient satisfaction, aesthetic results evaluating tissue color and texture were satisfactory; the pain was slight, obtaining a score of 2.10 ± 1.13 out of 10, measured using a Visual Analogue Scale (VAS). The present retrospective case series study shows that using an apically repositioned flap combined with a strip FGG and an XCM might offer a valid means of achieving KT gain.

Key Words: autografts, bone regeneration, dental implant, gingiva, xenogeneic collagen matrix

INTRODUCTION

Tooth extraction always leads to a certain number of dimensional changes to both soft and hard tissues.¹ The magnitude of these changes depends on several factors. So, different treatment approaches have been proposed to minimize or compensate for volume loss, including orthodontic extrusion,² ridge preservation,³ socket sealing,⁴ socket shield technique,⁵ soft tissue grafts⁶ and various bone augmentation techniques. Among the latter, horizontal and vertical bone regeneration effectively recovers bone dimensions and provides adequate conditions for placing implants with predictable

outcomes.⁷ In this context, severe hard tissue deficiencies require a large amount of graft material. So adequate flap passivation is essential to provide enough advancement for a tension-free suture, thereby minimizing the risk of tissue dehiscence. However, advanced bone reconstruction very often ends up causing severe mucogingival distortion (MGD), which includes reductions in keratinized tissue (KT) and vestibule depth (VD).⁸

The minimum dimension of KT around teeth and implants that will ensure adequate health remains to be determined.⁹ Nevertheless, some cases exhibit clear indications for mucogingival correction after significant reconstructive bone surgery.¹⁰ Moreover, the literature claims that the presence of an adequate band of KT is a critical factor for peri-implant health.¹¹ Several techniques have been proposed for increasing VD and KT using an apically repositioned flap (ARF) with either a free gingival graft (FGG)¹² or a connective tissue graft (CTG) in an open healing approach.¹³ These would obtain favorable results. Nevertheless, when significant mucogingival alterations are present, extensive grafting¹⁴ is often needed to correct them, leading to increased morbidity. It has been shown that masticatory mucosal grafts harvested from the palate can maintain tissue characteristics.¹⁵ However, color and texture mismatches with the adjacent tissue are frequently limited when using palatal grafts. To minimize

¹ Department of Dental Clinical Specialties, Faculty of Dentistry, Complutense University of Madrid, Spain.

² Department of Conservative Dentistry and Orofacial Prosthodontics, Faculty of Dentistry, Complutense University of Madrid, Spain.

³ Department of Oral Surgery and Oral Implantology, Faculty of Dentistry, University Alfonso X el Sabio, Madrid, Spain.

⁴ Department of Oral Surgery, School of Dental Medicine, University of Zagreb, Croatia.

⁵ Surgical and Implant Therapies in the Oral Cavity Research Group; University Complutense, Madrid, Spain.

* Corresponding author, e-mail: jcortesb@ucm.es
<https://doi.org/10.1563/aaaid-joi-D-23-00065>

patient morbidity and inadequate esthetic results, a xenogeneic collagen matrix (XCM) has been proposed as an alternative for producing KT gains.¹⁶ However, this increase may be insufficient in cases of severe mucogingival alteration. Thin FGG strips¹⁷ have also been recommended to reduce the need for extensive grafting. However, the secondary intention of healing exposed tissue can lead to the patient suffering significant levels of postoperative pain. Urban et al¹⁴ have proposed a combination of an XCM and a strip FGG as an advantageous alternative for restoring severe mucogingival distortions safely and effectively after advanced vertical and horizontal ridge augmentation procedures. This retrospective case series study evaluated the effectiveness, reproducibility, and predictability of this so-called "combination graft technique" regarding KT and VD gain, esthetic outcomes, and patient satisfaction.

MATERIALS AND METHODS

The present article followed STROBE (Strengthening the Reporting of Observational Studies in Epidemiology) guidelines. The Declaration of Helsinki conducted the study, and the protocol was approved by the Ethics Committee for Clinical Trials at the San Carlos Hospital, Madrid (Spain) (Reg. 22/292-E).

Twelve patients (8 women and 4 men) who had undergone vertical guided bone regeneration (GBR) procedures and implant placement in posterior regions were retrospectively enrolled in this case series study. All patients gave their written informed consent to participate in the study.

All fulfilled the following inclusion and exclusion criteria and were recruited from Madrid (Spain), private practice.

Inclusion criteria

Dentally and periodontally healthy patients.

Patient with no relevant systemic diseases (American Society of Anesthesiologists classification ASA I and ASA II).

The presence of KT reduction of ≤ 3 mm.

Patients with adequate oral hygiene.

Patients willing to follow pre- and postoperative indications and attend follow-up appointments.

Exclusion criteria

Heavy smokers (>10 cigarettes a day).

Patients with non-well-controlled systemic alterations.

Preoperative care

Every patient underwent professional cleaning/periodontal supportive therapy one week before surgery; 0.2% chlorhexidine digluconate rinses were recommended twice a day for 4 days before surgery. Antibiotic prophylaxis consisted of 2 g of amoxicillin 1 hour before surgery. No patient was allergic to penicillin.

Surgical protocol

All surgeries were performed by the same surgeon (R.M.E.). After adequate anesthetic administration (articaine/epinephrine 40/0.01 mg Ultracaine Normon), a split-thickness incision was made slightly coronal of the mucogingival line (MGL) using a 15C

blade 90° to the tissue. Mesial and distal oblique vertical split-thickness incisions reaching the fornix of the adjacent area were made as a continuation of the first incision. Rotating the blade parallel to the tissue, a superficial split-thickness flap was then elevated in the coronal part to provide a bleeding bed, while preserving as much tissue thickness as possible. Three to four millimeters apically, a split-thickness flap was prepared close to the periosteum, following the classic protocol for ARF. Mobile tissue, if present, was carefully removed. The flap was then apically sutured with T-mattress 5.0 resorbable suture (Glycolon Resorba).

After measuring the mesiodistal distance of the recipient site in its apical dimension, a strip FGG of 2–3 mm in width and 1.5–2 mm in thickness and site-correspondent length was harvested from the palate using a 15C blade. A hemostat agent (Surgicel, Somerville, NJ) was directly placed on the donor site. The strip was then sutured on the most apical end of the recipient site with a single interrupted and crossed horizontal mattress with 5.0 resorbable sutures (Glycolon Resorba), ensuring adequate adaptation and immobilization of the strip.

Finally, an XCM (Mucograft, Geistlich Biomaterials GmbH, Baden-Baden, Germany) was trimmed according to the non-covered recipient site dimensions and sutured below the strip FGG with an identical technique but using 5.0 resorbable sutures (Glycolon Resorba) to enhance tissue compatibility (Figure 1a–e).¹⁸

Postoperative care

Patients were instructed to rinse with 0.2% chlorhexidine digluconate twice a day for 10 days; antibiotic and anti-inflammatory medication consisted of amoxicillin 750 mg/8 h/7 d and ibuprofen 600 mg/8 h/5 d. Patients were told not to pull the lip for 1 week. Patients were scheduled for follow-up appointments 1 week after surgery and suture removal was carried out 2 weeks later.

Outcome measurements

In this study, a single independent investigator (R.J.T.), different from the surgeon who operated on the cases, measured 4 parameters: KT height, tissue thickness, morbidity, and color. Keratinized tissue height was measured using a calibrated periodontal probe CP12; vertical measurements were taken from the mucogingival line (MGL) to a line projected from the gingival zenith of the adjacent mesial tooth. These measurements were registered at baseline, on the day of surgery, and 24 months after surgery.

Tissue thickness was measured as follows: after the administration of anesthesia, the same probe with an endodontic stop was used to measure the thickness of the soft tissue by introducing it perpendicularly into the tissue until it reached the bone surface. The measurements were always taken in the same place (3 mm apical of the implant connection; if the patient had more than 1 implant, the measurement was always taken in relation to the mesial implant).

A VAS was used to evaluate morbidity and patient pain. Patients were asked to quantify the level of postoperative discomfort/pain on a 10-cm horizontal line where 0 corresponded to the absolute absence of discomfort and 10 to the extreme expression of pain 1 week after surgery (Figure 2).

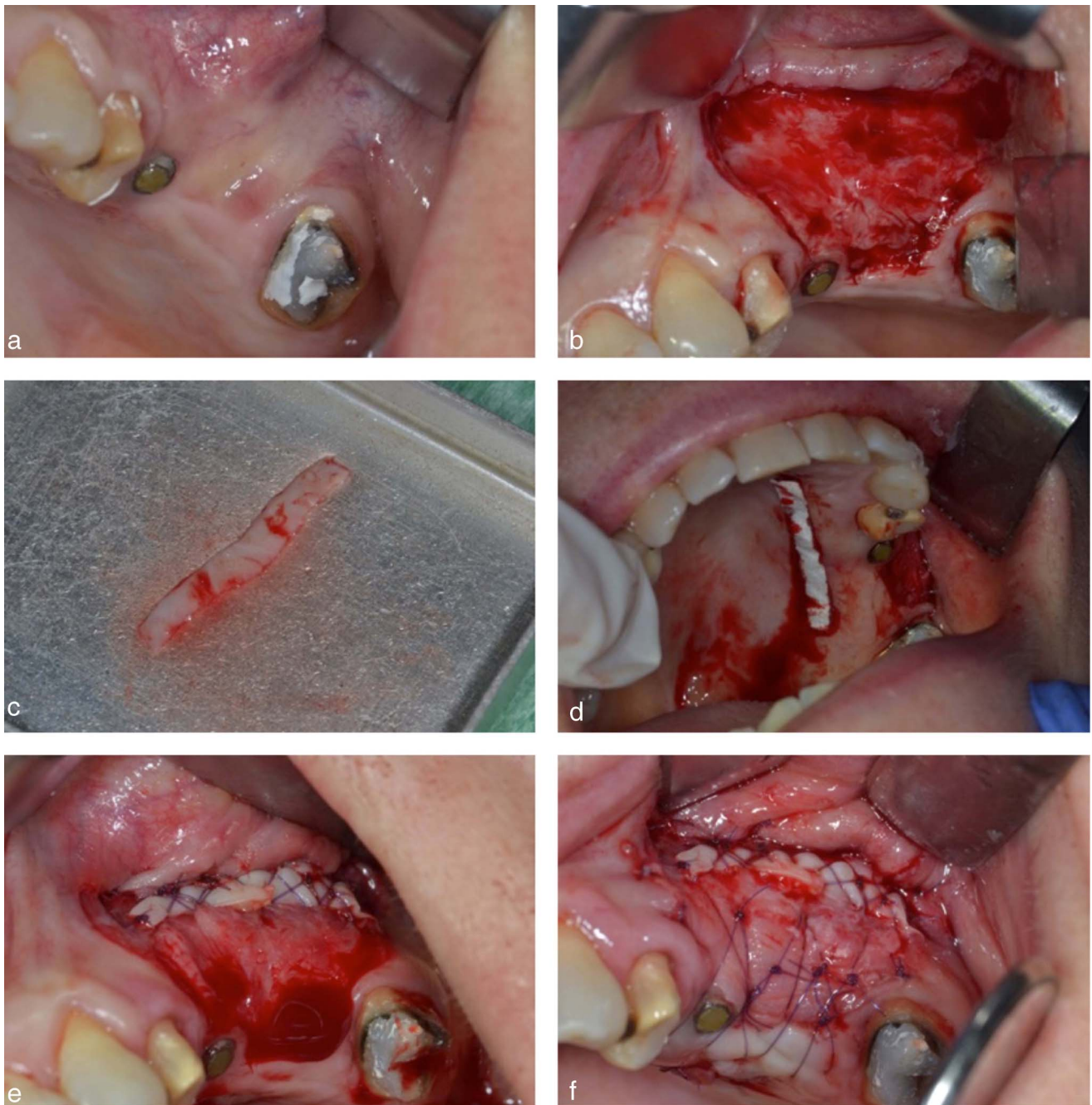


FIGURE 1. (a) Initial image of the case. (b) Repositioning of the flap. (c) Autologous graft of the palate. (d) Positioning of Surgicel. (e) Apical positioning of the autologous graft. (f) Positioning of the xenogeneic collagen matrix.

Esthetics were assessed at the 24-month follow-up appointment, when a visual assessment of color and texture difference between the graft and adjacent tissue was made, recording any color change with respect to adjacent tissues.

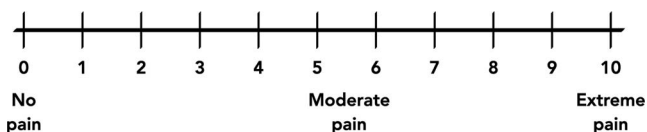


FIGURE 2. Visual Analogue Scale (VAS).

Data analysis

Descriptive statistics of the outcome measurements were presented as means, medians, SDs, and 95% CIs of the means.

RESULTS

A total of 12 patients (8 women and 4 men) with MGL distortion after vertical GBR procedures at posterior sites with subsequent implant placement were treated between October 2016 and December 2019 with modified ARFs and strip FGGs combined

Patient	Sex	Age	Maxilla/Mandible*	Complications
1	F	63	MX	No
2	F	60	MX	No
3	F	55	MB	No
4	F	67	MB	No
5	F	59	MX	No
6	M	63	MX	No
7	M	63	MB	No
8	M	63	MX	No
9	F	73	MX	No
10	F	61	MB	Palatal hemorrhage
11	M	63	MX	No
12	F	62	MB	No
Median		63		
Mean		62.67		
SD		4.36		
Lower 95% CI		60.50		
Upper 95% CI		63		

*MX indicates maxilla; MB, mandible.

with an XCM. The mean age of the patients was 62.67 years (SD: 4.36 years and 95% CI). Eight out of 12 surgeries were performed in the maxilla while 4 were in the mandible. Despite 1 patient suffering palatal bleeding a few hours after surgery, no patient suffered significant complications. Table 1 provides patients' clinical and demographic data. Every patient completed the 24-month follow-up program consisting of 1, 2, 3, and 4-weekly and 2, 3, 6, 12, and 24-monthly follow-up appointments (Figure 3a–e). The success rate of graft integration was 100%. Average Keratinized tissue height gain at 24 months was 5.33 mm (SD: 2.06 mm and 95% CI ranging between 2 and 8.5 mm) (6.29 mm in the maxilla and 4.64 mm in the mandible). The increase in tissue thickness was much more limited, obtaining a mean value of 0.42 mm (SD: 0.50 mm and 95% CI ranging between 0.5 and 1 mm). Table 2 shows the results of the variables measured. Patient satisfaction in terms of morbidity was high with a mean value of discomfort/pain perception of 2.10 cm (SD: 1.13 cm and 95% CI) (Table 3). The esthetic evaluation of color and texture matching to adjacent tissues was satisfactory as every case presented an acceptable color match with adjacent tissues (Figure 4).

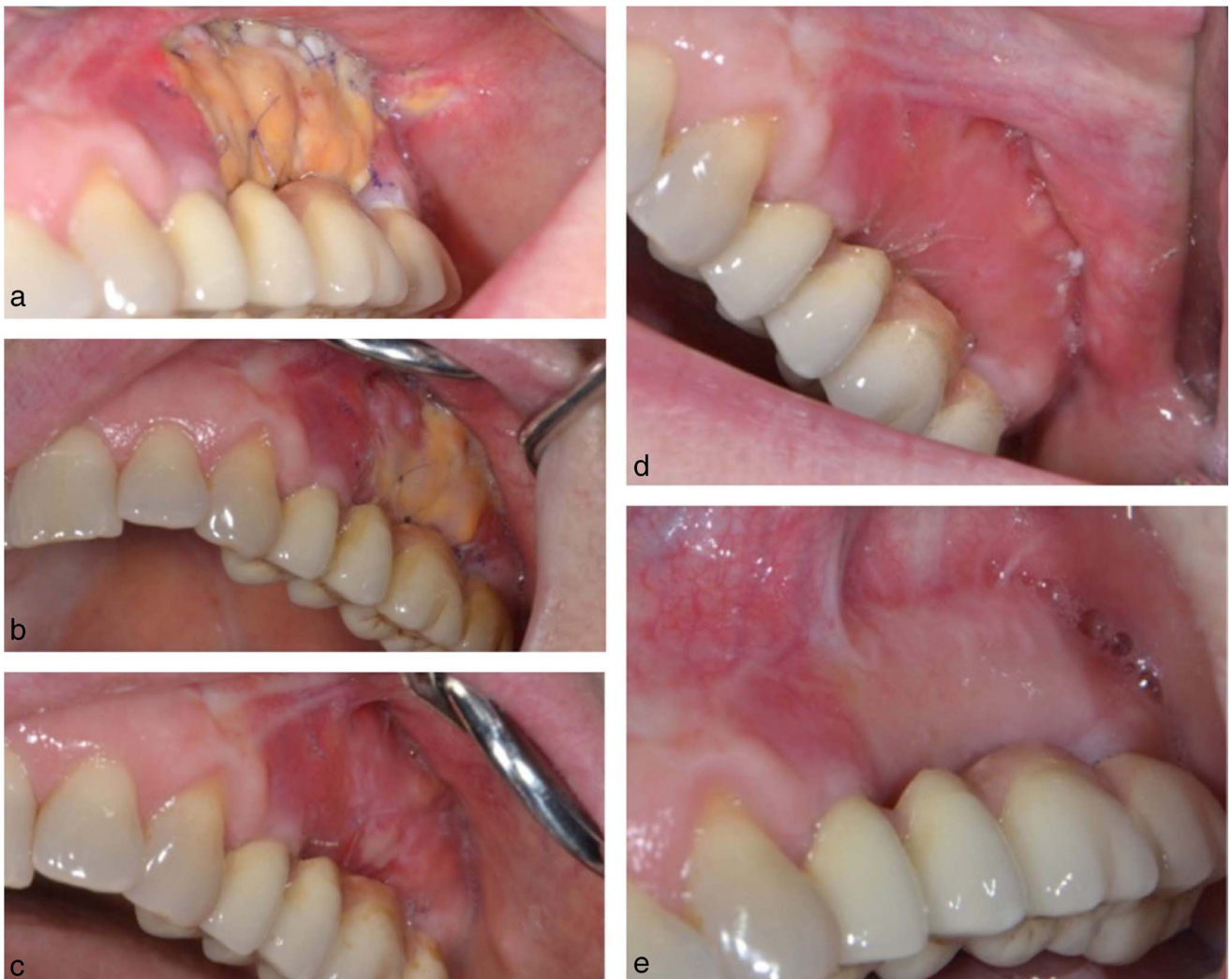


FIGURE 3. Check-ups. (a) Check-up after 1 week. (b) Check-up after 2 weeks. (c) Check-up after 3 weeks. (d) Check-up after 4 weeks. (e) Check-up after 3 months. Mature tissue.

TABLE 2
Results of the variables measured

Patient	Keratinized tissue achieved	Keratinized vestibule augmentation	Thickness augmentation	Initial thickness (mm)	Final thickness (mm)	Thickness augmentation (mm)	Initial keratinized vestibule (mm)	Final keratinized vestibule (mm)	Keratinized vestibule augmentation (mm)
1	Yes	Yes	Yes	2	2.5	0.5	1.5	8	6.5
2	Yes	Yes	Yes	3.5	4	0.5	2	7	5
3	Yes	Yes	No	3	3	0	1	6	5
4	Yes	Yes	Yes	2	3	1	2	4	2
5	Yes	Yes	Yes	3	4	1	2	9	7
6	Yes	Yes	Yes	3	4	1	3	6	3
7	Yes	Yes	No	2.5	2.5	0	1	5	4
8	Yes	Yes	No	2.5	2.5	0	2	10	8
9	Yes	Yes	Yes	2.5	3	0.5	1.5	7	5.5
10	Yes	Yes	No	3	3	0	1	4	3
11	Yes	Yes	No	1.5	1.5	0	1.5	10	8.5
12	Yes	Yes	Yes	2.5	3	0.5	1.5	8	6.5
Median				2.50	3.00	0.50	1.50	7.00	5.25
Mean				2.58	3.00	0.42	1.67	7.00	5.33
SD				0.56	0.74	0.42	0.58	2.09	2.06
Lower 95% CI				2.25	2.50	0.00	1.25	5.50	3.50
Upper 95% CI				3.00	3.50	0.75	2.00	8.50	6.75

DISCUSSION

The results of the present study show that, at the end of a 24-month follow-up, the combination of modified ARF with strip FGG and XCM provides a predictable and low-morbidity means of achieving significant KT height gain to restore MGL and vestibule depth after vertical GBR procedures. The esthetic results were also satisfactory obtaining acceptable tissue color and texture integration. However, the KT tissue thickness increase was minimal.

Advanced bone reconstruction procedures can lead to significant distortion of the MGL and reduced VD due to the extensive coronal flap advancement needed for adequate closure.¹⁹ In most cases, this clinical situation causes functional and esthetic problems.²⁰ The need for a minimum amount of peri-implant KT

has been an ongoing topic of debate⁹ and remains controversial. Nevertheless, well-designed systematic reviews¹¹ conclude that an adequate zone of KT is related to better peri-implant tissue health. A recent 4-year follow-up prospective study of 202 implants found associations between KT width and marginal bone loss, plaque accumulation, tissue inflammation and brushing discomfort, concluding that peri-implant KT ≥ 2 mm around implants appears to have a protective effect on peri-implant tissues.²¹ The present study obtained an average increase in KT height of 5.25 ± 2.06 mm (6.29 mm in the maxilla and 4.64 mm in the mandible), which may be considered adequate for peri-implant protection.

A recent study comprehensively assessed the effects of soft tissue thickness augmentation, finding significant improvements in gingival index, mucosal recession and plaque control derived from increased KT width.²² In the present study, tissue thickness gain was minimal, with a mean value of 0.42 ± 0.42 mm,

TABLE 3

Esthetic evaluation and postoperative patient morbidity

Patient	Color difference	Morbidity (cm)
1	No	2.8
2	No	2.1
3	No	2.6
4	No	1.6
5	No	0
6	No	3.1
7	No	3.2
8	No	2.8
9	No	1
10	No	3.5
11	No	0.4
12	No	2.1
Median		2.35
Mean		2.10
SD		1.13
Lower 95% CI		1.30
Upper 95% CI		2.95

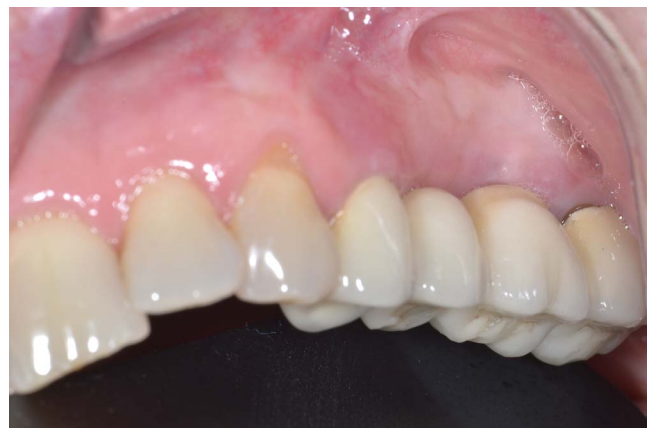

FIGURE 4. Check-up after 24 months, with a definitive fixed dental prosthesis.

although thickness augmentation was not a treatment objective. Several techniques have been proposed for increasing peri-implant KT and vestibule depth, including an ARF in combination with an FGG or a CTG; these have obtained favorable results.¹³ Nevertheless, harvesting autogenous soft tissue grafts is often associated with patient morbidity due to the need for a second surgical site.¹⁴ So, to minimize discomfort or pain after KT augmentation using techniques employing autogenous grafts, an XCM has been recommended as an optimal treatment option.¹⁶ A recent randomized clinical trial (RCT) comparing the use of an XCM versus a CTG to increase buccal soft tissue thickness at 60 implant sites found that the use of XCM was associated with significantly less chair-time, less postoperative pain, less painkiller intake, and greater patient satisfaction with the final outcome.²³ Similar results were reported in a previous RCT evaluating patient morbidity and satisfaction with XCM around teeth.²⁴

In addition to morbidity and chair time reductions, other advantages have been reported when comparing an XCM with a CTG. It is well known that when transplanting a graft from the palate, genetic information from the donor site is transplanted to the recipient site, so color and texture mismatches are a frequent esthetic complication when using autogenous grafts harvested from the palate. These can be avoided by using an XCM.²⁵ A recent prospective study evaluating patients report outcome measures (PROMs) found that patients preferred the aesthetics of implants with a zone of KT with a statistically significant difference. However, its presence or absence did not affect brushing discomfort.²⁶

From a histological standpoint, human and animal studies have observed good integration of XCM at the recipient site with no signs of adverse tissue reaction or significant inflammatory responses.²⁷

Although the use of an XCM would appear to offer an advantageous method in terms of color matching, morbidity and chair-time,²⁸ some authors have questioned its capacity for KT gain as XCMs do not provide the cellular component needed for KT formation²⁹ and have shown worse clinical outcomes in terms of KT height gain compared with FGGs or CTGs.¹⁷ To overcome this limitation, Urban et al¹⁴ proposed an approach based on the classic strip FGG technique involving the combination of an XCM with a strip FGG. This innovative technique provides an FGG cell source that promotes cellular migration and differentiation to the XCM.³⁰ At the same time, the apical positioning of this FGG works as a mechanical barrier for repositioning the MGL, deepening the vestibule,²⁰ while the XCM provides a healing repository for KT.³⁰ Moreover, as the matrix covers the periosteal bed, which would otherwise be exposed for open healing, and as the size of the strip FGG is significantly smaller than in traditional approaches, patient morbidity reported in the original case series study¹⁴ was low, and mean pain was 2.35 out of 10 on the VAS. These findings are in accordance with the present results, in which patients reported low postoperative pain/discomfort, with a mean score of 2.10 ± 1.13 out of 10 on the VAS.

A recent histological study in humans compared the biopsy result of FGG+XCM with FGG harvested at 1 year postoperatively, observing that both samples appeared identical.³⁰ Regarding esthetics, the regenerated tissue showed an adequate color match with adjacent tissues, except in the FGG strip. Similar results were

obtained in the present study, as adequate color and texture matches were found in all cases at the 6-month examination.

It should be noted that the present study suffered certain biases that may have affected the results, particularly the low number of patients, asymmetric gender distribution, and surgical site measurement locations.

CONCLUSION

Nevertheless, within these limitations, the use of a modified ARF with a strip FGG and an XCM would appear to offer a practical, reproducible and predictable method for vestibule deepening, adequate KT gain, and MGL repositioning with a satisfactory aesthetic outcome, low morbidity and high patient satisfaction after advanced vertical bone augmentation procedures.

ABBREVIATIONS

ASA: American Society of Anesthesiologists classification
 ARF: Apically repositioned flap
 Cis: Confidence intervals
 CTG: Connective tissue graft
 FGG: Free gingival graft
 GBR: Guided bone regeneration
 KT: Keratinized tissue
 MGD: Mucogingival distortion
 MGL: Mucogingival line
 PROMs: Patients report outcome measures
 RCT: Randomized clinical trial
 STROBE: Strengthening the Reporting of Observational Studies in Epidemiology
 VAS: Visual Analogue Scale
 VBA: Vertical bone augmentation
 VD: Vestibule depth
 XCM: Xenogeneic collagen matrix

NOTE

The authors declare no conflicts of interest related to this study.

REFERENCES

- Chappuis V, Engel O, Reyes M, Shahim K, Nolte LP, Buser D. Ridge alterations post-extraction in the esthetic zone: a 3D analysis with CBCT. *J Dent Res*. 2013;92(suppl 12):1955–2015.
- Alsahhaf A, Att W. Orthodontic extrusion for pre-implant site enhancement: principles and clinical guidelines. *J Prosthodont Res*. 2016;60:145–155.
- Vignoletti F, Matesanz P, Rodrigo D, Figuero E, Martin C, Sanz M. Surgical protocols for ridge preservation after tooth extraction. A systematic review. *Clin Oral Implants Res*. 2012;23(suppl 5):22–38.
- Tan-Chu JH, Tuminelli FJ, Kurtz KS, Tarnow DP. Analysis of buccolingual dimensional changes of the extraction socket using the “ice cream cone” flapless grafting technique. *Int J Periodontics Restorative Dent*. 2014;34:399–403.
- Sáez-Alcaide LM, Fernández-Tresguerres FG, Brinkmann JC, et al. Socket shield technique: a systematic review of human studies. *Ann Anat*. 2021;1:151779.
- Zuhr O, Bäumer D, Hürzeler M. The addition of soft tissue replacement grafts in plastic periodontal and implant surgery: critical elements in design and execution. *J Clin Periodontol*. 2014;41(suppl 15):S123–S142.
- Simion M, Jovanovic SA, Tinti C, Benfenati SP. Long-term evaluation of osseointegrated implants inserted at the time or after vertical ridge augmentation. A retrospective study on 123 implants with 1-5 year follow-up. *Clin Oral Implants Res*. 2001;12:35–45.
- Urban IA, Lozada JL, Jovanovic SA, Nagursky H, Nagy K. Vertical ridge augmentation with titanium-reinforced, dense-PTFE membranes and a combination of particulated autogenous bone and anorganic bovine bone-derived

mineral: a prospective case series in 19 patients. *Int J Oral Maxillofac Implants*. 2014;29:185–193.

9. Zigdon H, Machtei EE. The dimensions of keratinized mucosa around implants affect clinical and immunological parameters. *Clin Oral Implants Res*. 2008;19:387–392.

10. Urban IA. Guided bone regeneration: vertical growth. In: Sonick M, Hwang D, eds. *Implant Site Development*. West Sussex, UK: Wiley; 2012:216–231.

11. Schmitt CM, Moest T, Lutz R, Wehrhan F, Neukam FW, Schlegel KA. Long-term outcomes after vestibuloplasty with a porcine collagen matrix (Mucograft) versus the free gingival graft: a comparative prospective clinical trial. *Clin Oral Impl Res*. 2016;27:e125–e133.

12. Sullivan HC, Atkins JH. Free autogenous gingival grafts. I. Principles of successful grafting. *Periodontics*. 1968;6:121–129.

13. Edell A. Clinical evaluation of free connective tissue grafts used to increase the width of keratinized gingiva. *J Clin Periodontol*. 1974;1:185–196.

14. Urban I, Lozada J, Nagy K, Sanz M. Treatment of severe mucogingival defects with a combination of strip gingival grafts and a xenogeneic collagen matrix: a prospective case series study. *Int J Periodontics Restorative Dent*. 2015;35:345–353.

15. Karring T, Ostergaard E, Löe H. Conservation of tissue specificity after heterotopic transplantation of gingiva and alveolar mucosa. *J Periodontol Res*. 1971;6:282–293.

16. Lorenzo R, García V, Orsini M, Martin C, Sanz M. Clinical efficacy of a xenogeneic collagen matrix in augmenting keratinized mucosa around implants: a randomized controlled prospective clinical trial. *Clin Oral Implants Res*. 2012;23:316–324.

17. Han TJ, Takei HH, Carranza FA. The strip gingival autograft technique. *Int J Periodontics Restorative Dent*. 1993;13:180–187.

18. Leknes KN, Selvig KA, Bøe OE, Wikesjö UM. Tissue reactions to sutures in the presence and absence of anti-infective therapy. *J Clin Periodontol*. 2005;32:130–138.

19. McGuire MK, Tavelli L, Feinberg SE, et al. Living cell-based regenerative medicine technologies for periodontal soft tissue augmentation. *J Periodontol*. 2020;91:155–164.

20. Urban IA. *Vertical 2, The Next Level*. Quintessence Publishing; 2021.

21. Perussolo J, Souza AB, Matarazzo F, Oliveira RP, Araújo MG. Influence of the keratinized mucosa on the stability of peri-implant tissues and brushing discomfort: a 4-year follow-up study. *Clin Oral Implants Res*. 2018;29:1177–1185.

22. Thoma DS, Cosyn J, Fickl S, et al; Working Group 2 of the 6th EAO Consensus Conference 2021. Soft tissue management at implants: summary and consensus statements of group 2. The 6th EAO Consensus Conference 2021. *Clin Oral Implants Res*. 2021;32(suppl 21):174–180.

23. Cairo F, Barbato L, Tonelli P, Batalocco G, Pagavino G, Nieri M. Xenogeneic collagen matrix versus connective tissue graft for buccal soft tissue augmentation at implant site. A randomized, controlled clinical trial. *J Clin Periodontol*. 2017;44:769–776.

24. McGuire MK, Scheyer ET. Randomized, controlled clinical trial to evaluate a xenogeneic collagen matrix as an alternative to free gingival grafting for oral soft tissue augmentation. *J Periodontol*. 2014;85:1333–1341.

25. Rohn AR, Zare H, Haddadi P. Use of mucograft collagen matrix versus free gingival graft to augment keratinized tissue around teeth: a randomized controlled clinical trial. *Front Dent*. 2020;17:5.

26. Bonino F, Steffensen B, Natto Z, Hur Y, Holtzman LP, Weber HP. Prospective study of the impact of peri-implant soft tissue properties on patient-reported and clinically assessed outcomes. *J Periodontol*. 2018;89:1025–1032.

27. Jung RE, Hurzeler MB, Thoma DS, Khraisat A, Hammerle CH. Local tolerance and efficiency of two prototype collagen matrices to increase the width of keratinized tissue. *J Clin Periodontol*. 2011;38:173–179.

28. Tavelli L, McGuire MK, Zucchelli G, et al. Extracellular matrix-based scaffolding technologies for periodontal and peri-implant soft tissue regeneration. *J Periodontol*. 2020;91:17–25.

29. Yu SH, Tseng SC, Wang HL. Classification of soft tissue grafting materials based on biologic principles. *Int J Periodontics Restorative Dent*. 2018;38:849–854.

30. Urban IA, Nagy K, Werner S, Meyer M. Evaluation of the combination of strip gingival grafts and a xenogeneic collagen matrix for the treatment of severe mucogingival defects: a human histologic study. *Int J Periodontics Restorative Dent*. 2019;39:9–14.